Association Between Injury Mechanisms and Magnetic Resonance Imaging Findings in Rectus Femoris Injuries in 105 Professional Football Players

Rafael Cristiano Geiss Santos, MD,* Frank Van Hellemnondt, MD,*† Eduardo Yamashiro, MD,* Louis Holtzhausen, PhD,*‡ Andreas Serner, PhD,* Abdulaziz Farooq, MSc, MPH,* Rodney Whiteley, PhD,* and Johannes L. Tol, PhD*§¶

Abstract

Objective: To describe the injury mechanism and its association with magnetic resonance imaging (MRI) injury findings in acute rectus femoris injuries. **Design:** Combined retrospective and prospective descriptive injury study. Retrospective cohort from January 2010 to October 2013 and prospective cohort from October 2013 to January 2019. **Setting:** Specialized sports medicine hospital. **Participants:** Male professional football players older than 18 years playing in a national football league, referred for injury assessment within 7 days after an acute rectus femoris injury, with a positive finding on MRI. **Independent variables:** Rectus femoris muscle injury MRI findings in relation to injury mechanism in male football players. **Main outcome measures:** Rectus femoris injury mechanism (kicking, sprinting, and others), MRI injury location, and grade. **Results:** There were 105 injuries in total, with 60 (57.1%) and 45 (42.8%) injuries from the retrospective and prospective cohorts, respectively. Kicking was the injury mechanism in 57 (54.3%) of all acute rectus femoris injuries, sprinting represented 32 (30.4%), and 16 (15.2%) were classified as others. There were 20 (19.05%) free tendon, 67 (63.8%) myotendinous junction and/or intramuscular tendon, and 18 (17.1%) peripheral myofascial located injuries. All free tendon injuries were related to kicking and graded as a complete tear of at least one of the tendons in 15/20 (75.0%) cases. **Conclusions:** Kicking seems to be an important mechanism related to complete ruptures and injuries occurring at the proximal free tendon. Sprinting was the other most common mechanism but was never associated with injury to the proximal free tendon.

Key Words: rectus femoris, muscle injuries, thigh, quadriceps, imaging, football

(*Clin J Sport Med* 2021;00:1–6)

INTRODUCTION

Thigh injuries are the most common muscle injuries in football (soccer).[1,2] In professional football, 79% of all muscle injuries occur in the thigh, of which 19% are related to the quadriceps,[1] predominantly in the rectus femoris muscle.[3] Acute anterior thigh muscle injuries cause longer time loss than posterior thigh (hamstring) injuries.[1,2] Despite its prevalence and relative high reinjury rate (up to 17%),[1,4] the current literature is limited to five prospective cohort studies[3,5–8] including less than 100 rectus femoris injuries in total.

Submitted for publication October 24, 2020; accepted March 28, 2021.

*From the *Aspetar Orthopedic and Sports Medicine Hospital, Doha, Qatar; †De Sportartsen Groep OLVG West, Amsterdam, the Netherlands; ‡Division Sports Medicine, University of Pretoria, Pretoria, South Africa; §Academic Center of Evidence-Based Sports Medicine (ACES), Amsterdam UMC, Amsterdam, the Netherlands; and ¶Amsterdam Collaboration for Health and Safety in Sports (ACHSS), Amsterdam UMC IOC Research Center, Amsterdam, the Netherlands.*

The authors report no conflicts of interest.

Corresponding Author: Rafael Cristiano Geiss Santos, MD, Aspetar Orthopedic and Sports Medicine Hospital, Doha, Qatar 29222 (rafael.santos@aspetar.com).

Copyright © 2021 Wolters Kluwer Health, Inc. All rights reserved.

http://dx.doi.org/10.1097/JSM.0000000000000935

Injuries are mostly related to kicking and sprinting mechanisms.[9–12] Imaging plays an important role in determining the type of tear, topography, and severity.[9] Rectus femoris injuries typically involve the free tendon portion, the myotendinous junction (MTJ) (most common site of tear), the myofascial junction, and its surrounding connective tissues.[9,13]

There is insufficient evidence to indicate whether an association exists between injury mechanism and MRI findings of acute rectus femoris injuries as injury mechanism has not been detailed in previous studies, including kicking sports.[3,14,15]

The aim of our study was to describe the injury mechanism and its association with MRI injury findings in acute rectus femoris injuries.

MATERIALS AND METHODS

Study Design and Participants

In this descriptive injury study, we included a retrospective cohort from January 2010 to October 2013 and a prospective cohort, from October 2013 to January 2019. We included

Copyright © 2021 Wolters Kluwer Health, Inc. Unauthorized reproduction of this article is prohibited.

Clinical Relevance

Rectus femoris injuries represent an important injury in professional football. Quadriceps injuries represent one-fifth of acute muscle injuries in football,[1] and most of these involve the rectus femoris muscle.[3] The current literature in acute rectus femoris muscle injuries is limited to five prospective cohort studies[3,5–8] including less than 100 injuries in total. There is little information regarding the association between rectus femoris injury and magnetic resonance imaging (MRI) findings or injury mechanism. Understanding the injury mechanism and correlation with MRI location and grading will help clinicians to evaluate acute rectus femoris injuries in football.

Kicking seems to be an important mechanism related to complete ruptures and injuries occurring at the proximal free tendon. Sprinting was the other most common mechanism but was never associated with a complete injury to the proximal free tendon. Clinicians should be very suspicious for complete free tendon ruptures in kicking injury mechanism when there are proximally located symptoms.

Future studies and further analysis are recommended to investigate how the injury mechanism, MRI location, and grading might impact clinical outcome scores, time to return to play, and risk of reinjury rates.

male professional football players older than 18 years from the Qatar Stars League of football, referred to a specialized secondary sports medicine center for injury assessment within 7 days after an acute indirect rectus femoris injury, with a positive injury finding on MRI.[16,17]

For the retrospective cohort, we searched the injury registration system. This injury registration system is a standardized hospital system in which the consulting sports medicine physician prospectively records standardized injury details, including demographics, injury mechanism, and injury location. Second, we searched the hospital's picture archiving and communication system for MRI scans of the thigh from January 1, 2010, to October 2013 and selected the MRI-positive anterior thigh injuries.

For the prospective cohort, we standardized injury registration on a study-specific data collection form, including clinical history recorded by a sports medicine physician, injury time (training/match), injury mechanism, leg dominance, and anthropometric data. Standardized MRI investigation was performed within 7 days of initial injury. Participants from a concomitant prospective study[6,18] meeting the inclusion criteria were also included.

Ethical approval was obtained from the Shafallah Medical Genetics Center Institutional Review Board (IRB#: 2012-018, #2012-013) and the Anti-Doping Lab Qatar Institutional Review Board (IRB#: EXT 2014000009, #EXT 2014000004). For the prospective cohort, written informed consent was acquired from all athletes before inclusion.

Injury Mechanism

The injury mechanism was categorized as kicking, sprinting, and others (those cases not related to kicking, sprinting, and/or where the athletes could not specify the exact injury mechanism but described an acute onset of pain felt during football-related activities). The dominant leg was defined as the preferred leg for kicking, categorized as right, left, or both for ambidexterity.

MRI Protocol

MRI was conducted using either a 1.5 Tesla (Siemens Espree) or a 3.0 Tesla (GE Discovery 750 w), using standard imaging protocols that included axial and coronal STIR sequences along the longitudinal axis of the thigh (TR/TE 3710/28, inversion time 160 and a 192 × 256 matrix for the coronal images and TR/TE 3660/27, inversion time 160 and a 162 × 256 matrix for the axial images), with one signal average each were obtained with the Siemens Espree. The field of view (FOV) on the coronals was 35 cm, 5-mm slice thickness with 1.5-mm gap and 30 cm with the axial images, 6-mm section thickness with 2-mm gap. Axial and coronal T2 fat-saturated along the longitudinal axis of the thigh (TR/TE 5801/90 and a 320 x 320 matrix for the coronal images and TR/TE 6812/101 and a 320 x 320 matrix for the axial images), with one signal average each, were obtained with the GE Discovery. FOV on the coronals was 30 cm, 5-mm slice thickness with 2.0-mm gap and 32 cm with the axial images with a 5-mm slice thickness with 2-mm gap.

MR Assessment and Grading

Imaging interpretation of subjects with rectus femoris injury was performed by a musculoskeletal radiologist with more than 15 years' clinical experience (E.Y.).

We described the rectus femoris muscle injuries according to the anatomical nomenclature, describing the location of the lesion on MRI[9,10] in three main locations: (1) free tendon, (2) myotendinous (including intramuscular tendon), and (3) myofascial.

The free tendon was classified with 3 injury types: the proximal direct, indirect, or conjoined tendon (from the proximal insertion to the most proximal MTJ).[9,10] The myotendinous injuries included the MTJ of the direct tendon and the indirect tendon (intramuscular central tendon). The myofascial location included peripheral injuries and surrounding connective tissues.[9,13,19] Figure 1 depicts different MRI rectus femoris locations.

Free tendon injuries were classified as complete or partial tendon tears.[10,20] Criterion for complete tear was nonvisualization of tendinous structure or presence of full-thickness discontinuity with fluid signal intensity (SI) on T2-weighted images, whereas criterion for partial tear detection was fluid-like hyperintense SI partially disrupting the tendon on T2-weighted images.[20]

All MRI-positive acute lesions were graded on a scale from 1 to 3,[21,22] with grade 1: diffuse intramuscular hyperintensity representing edema, without architectural distortion; grade 2: edema with architectural distortion (partial tear); and grade 3: avulsions or complete musculotendinous disruptions.

Central tendon disruption, defined as an irregular wavy contour or focal defect separating proximal and distal parts of the tendon, was scored as present or absent.[23] In addition, a degloving injury,[24] represented as either a partial or complete dissociation between the inner muscle belly from the outer muscle with or without associated retraction,[24] was also scored as present or absent. Negative (grade 0) MRI was not included in the study.

Copyright © 2021 Wolters Kluwer Health, Inc. Unauthorized reproduction of this article is prohibited.

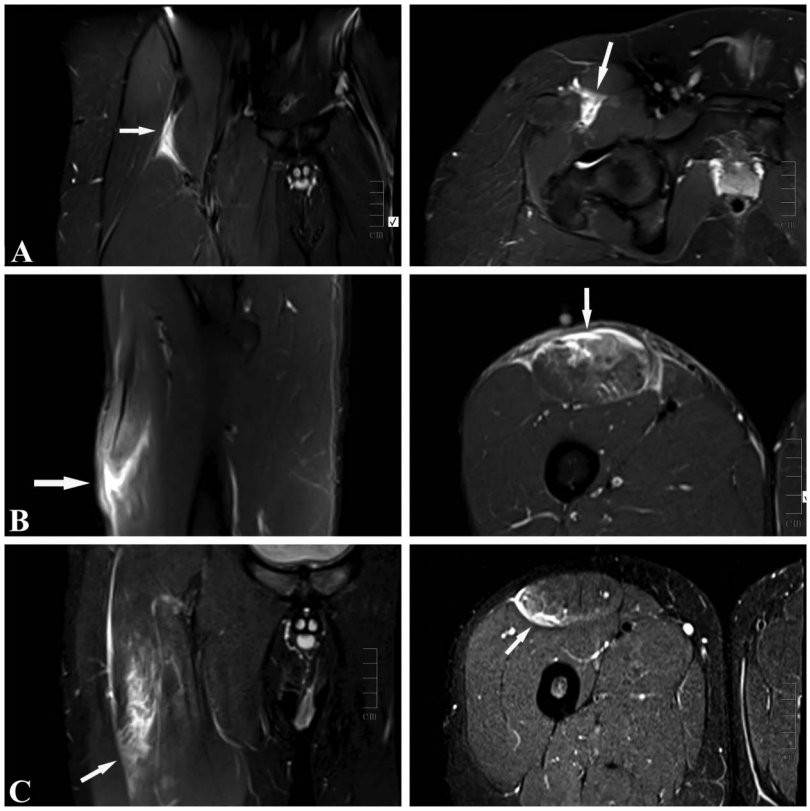

Figure 1. Rectus femoris injury location types. A, Proximal free tendon (FT), B, central myotendinous junction (MTJ), and C, myofascial (MF). A, Coronal and axial fluid-sensitive views of a complete tear of the proximal free tendon (white arrows). B, Sagittal and axial fluid-sensitive views of a grade 3 injury of the central tendon of the indirect myotendinous junction (white arrows). C, Coronal and axial fluid-sensitive views of a grade 2 posterolateral myofascial injury.

Statistical Analysis

Data were coded and analyzed using SPSS version 21.0. Mean and SD were reported for continuous variables and frequencies and proportion for categorical variables. The χ^2 test was used to test the association between categorical variables such as injury grade, dominant side with rectus femoris structures, and injury mechanism. The level of significance was set at a P value <0.05.

RESULTS

A total of 105 MRI-positive acute rectus femoris muscle injuries in male football players were included. There were 60 (57.1%) and 45 (42.8%) injuries from the retrospective and prospective cohorts, respectively. The mean age was 25 years (±4.8 years), height 175 cm (±7.6 cm), and body mass 73 kg (±13.8 kg). Leg dominance was known in 91 (86%) cases, and 61 (58.0%) injuries occurred in the dominant leg.

Injury Mechanism

Kicking was the injury mechanism in 57 (54.3%) of all acute rectus femoris injuries. Sprinting represented 32 (31.3%) of the injuries, and 16 (15.2%) were classified as others (Figure 2). The overall distribution of injury mechanisms at three MRI locations is detailed in the Figure 3A–C.

Injury mechanism in relation to MRI findings is presented in Table 1.

All free tendon injuries were related exclusively to kicking (N = 20) and graded as a complete tear of at least one of the tendons in 15 of 20 (75.0%) cases, with partial tear in 5 of 20 cases (25.0%). There was a significant association between MRI injury location and injury mechanism ($P < 0.001$). There was no association between MRI grade and injury mechanism. The MRI grading of the myotendinous and myofascial kicking injuries was grade 1 in 13 of 37 cases (35.1%) grade 2 in 18 of 37 cases (48.6%)and grade 3 in 6 of 37 cases (16.2%). Sprinting-type injuries were grade 1 in 10 of 32 cases (31.3%), grade 2 in 19 of 32 cases (59.4%), and the remaining 3 (9.4%) were grade 3. Of the 16 other-mechanism cases, there were 9 (56.25%) grade 1 injuries, 6 (37.5%) grade 2, and grade 3 in 1 (6.25%) case.

MRI Injury Location and Grading

There were 20 (19.5%) free tendon, 67 (63.8%) MTJ and/or intramuscular tendon, and 18 (17.1%) peripherally located myofascial injuries.

There were 20 free tendon injuries; in 15 (75.0%) of these, there was a complete proximal free tendon tear. Of these 15, there were 4 each involving the free direct tendon only, the free indirect tendon only, the free conjoined tendon, and 3 combined complete free direct tendon and incomplete free indirect tendon injury. In 5 cases (25.0%), there was partial tear, 3 involving the free direct tendon, and 1 each involving the free indirect tendon or both free tendons.

Of the 67 (63.8%) MTJ and/or intramuscular tendon injuries, 60 (89.6%) involved the indirect tendon, including

Copyright © 2021 Wolters Kluwer Health, Inc. Unauthorized reproduction of this article is prohibited.

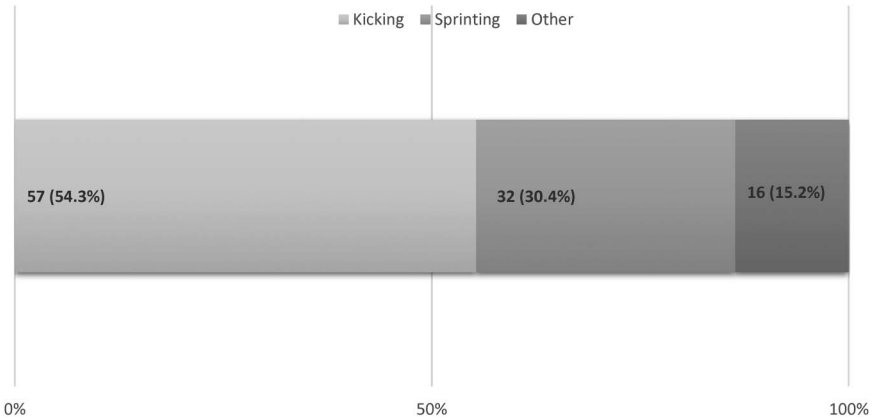

Figure 2. The overall distribution of injury mechanisms (absolute percentage within brackets). Overall, kicking was the most common injury mechanism (N = 57, 54.3%).

44 (65.6%) indirect only, 15 both (22.4%), and 1 case (1.6%) indirect associated with myofascial injury. The central intramuscular tendon was disrupted in 17 (25.4%) cases. Degloving injuries were found in 6 (8.9%) of these cases. From the MTJ injuries, grade 1 occurred in 21 (31.3%), grade 2 in 36 (53.7%), and grade 3 in 10 (14.9%) of them. Peripheral myofascial injuries occurred in 18 (17.1%) cases and were scored as grade 1 in 11 (61.1%) and grade 2 in 7 (38.8%). There was no association between injury mechanism and direct or indirect tendon for MTJ.

DISCUSSION

With a total of 105 football players, our clinical study on acute rectus femoris injury mechanism and MRI location is larger than all previous cohort studies reported.[3,5–8] We identified five key findings. First, more than half of injuries occurred during kicking. Second, one of five injuries were proximal free tendon injuries. Third, these free tendon injuries were exclusively caused by kicking (not sprinting). Fourth, three of four proximal free tendon injuries were complete ruptures of at least one of the free tendons. Fifth, most injuries were

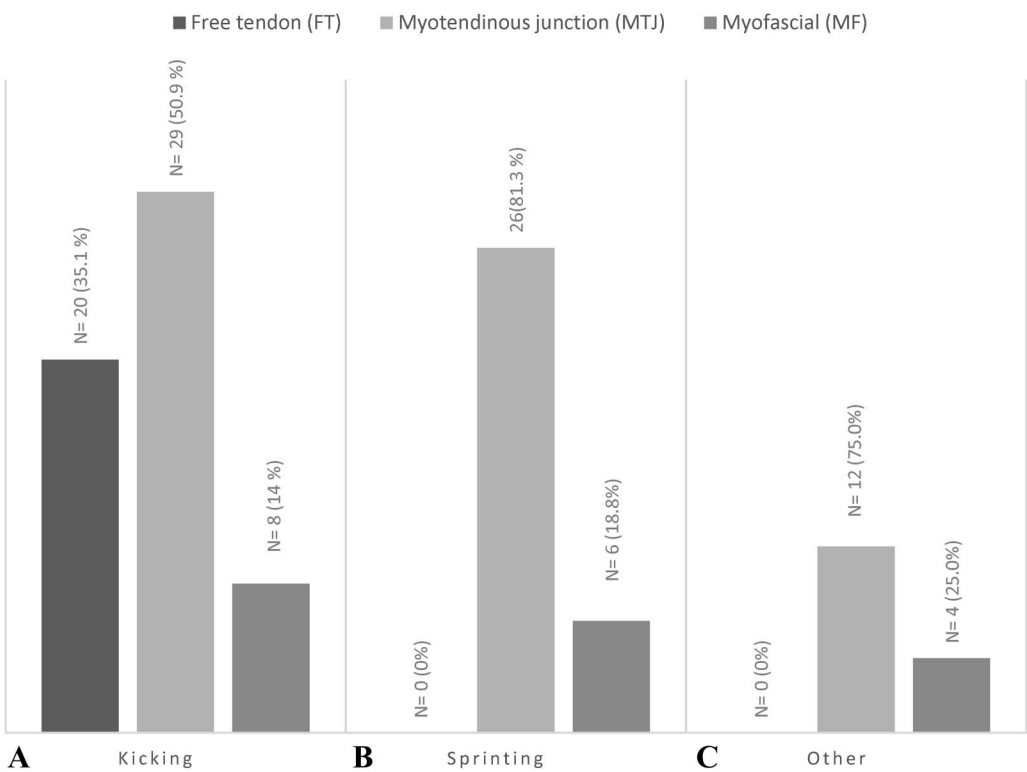

Figure 3. A–C, (A) Distribution of kicking injuries, (B) sprinting injuries, and (C) other injury mechanism at three MRI locations at three MRI locations (free tendon, myotendinous junction, and myofascial). For each injury mechanism, the absolute (N) and relative distribution (percentage within brackets) is presented. All 20 proximal free tendon (FT) injuries were due to kicking.

Copyright © 2021 Wolters Kluwer Health, Inc. Unauthorized reproduction of this article is prohibited.

TABLE 1. Injury Mechanism and MRI Injury Findings in Acute Rectus Femoris Injuries

	Kicking	Sprinting	Others	Total	
	N = 57 (54.3%)	N = 32 (30.4%)	N = 16 (15.2%)	N = 105 (100%)	*P*
Age	25 (±4.5)	25 (±5.3)	22 (±4.0)	25 (±4.8)	
Height	175 (±7.7)	174 (±7.2)	176 (±8.4)	175 (±7.6)	
Weight	73 (±13.1)	72 (±10.6)	76 (±21.1)	73 (±13.8)	
MRI injury location					
FT	20 (35.1)	0 (0.0)	0 (0.0)	20 (19.0)	<0.001
MTJ	29 (50.9)	26 (81.3)	12 (75.0)	67 (63.8)	
MF	8 (14.0)	6 (18.8)	4 (25.0)	18 (17.1)	
Complete/partial (FT)					
Complete	15 (75.0)	0 (0.0)	0 (0.0)	15 (75.0)	—
Partial	5 (25.0)	0 (0.0)	0 (0.0)	5 (25.0)	
MRI grade (MTJ and MF)					
Grade 1	13 (35.1)	10 (31.3)	9 (56.25)	32 (37.6)	0.155
Grade 2	18 (48.6)	19 (59.4)	6 (37.5)	43 (50.6)	
Grade 3	6 (16.2)	3 (9.4)	1 (6.25)	10 (11.8)	
Direct/indirect tendon (FT)					
Direct	7 (35.0)	0 (0.0)	0 (0.0)	7 (35.0)	—
Indirect	5 (25.0)	0 (0.0)	0 (0.0)	5 (25.0)	
Combined	8 (40.0)	0 (0.0)	0 (0.0)	8 (40.0)	
Direct/indirect tendon (MTJ)					
Direct	3 (10.3)	4 (15.4)	0 (0.0)	7 (10.4)	0.333
Indirect	18 (62.1)	16 (61.5)	11 (91.7)	45 (67.2)	
Combined	8 (27.6)	6 (23.1)	1 (8.3)	15 (22.4)	

Anthropometric data (age, height, and weight) are reported in yr, cm, and kg as mean (SD). Numbers are reported as N (column %). The column percentages are computed based on valid count for each category.
FT, free tendon; MF, myofascial.

located at the intramuscular MTJ and/or tendon with an equal distribution of kicking or sprinting mechanism.

Clinicians should be very suspicious for complete ruptures in kicking injury mechanism when there are proximally located injuries. Kicking was the injury mechanism in 55% of cases in this series. This association with kicking seems to be higher than in other football-related muscle injuries such as adductors (<30%)[6,25] and hamstrings (4%).[17] This finding has implications for injury prevention and rehabilitation programs. Future research could quantify the loads through rectus femoris structures during kicking and better inform preparticipation and rehabilitation processes.

The observation that the proximal free tendon injuries are exclusively related to kicking has not been previously reported. It suggests that kicking mechanism may cause increased damage to the proximal connective tissues of the free tendon. We speculate that these findings may be comparable with the relationship between injury mechanism and injured structure seen in the hamstrings stretching-type injuries. These injuries predominantly affect the proximal free tendon of the semimembranosus muscle, while sprinting-type injuries are more likely to affect the biceps femoris muscle.[26,27]

In our study, three of four of the free tendon injuries were complete tendon tears. The complete free tendon tears equally affected the proximal free direct and the indirect tendons. This contrasts with a previous study where a progression of acute injury affecting initially the indirect tendon of rectus femoris tendon origin, progressing to the direct tendon and eventually the conjoint tendon in more severe cases, was suggested.[20] Sixty-four percent of all rectus femoris injuries were located at the intramuscular MTJ and/or intramuscular tendon. This is comparable with a previous study, in which this was the most common injury location in football players.[7]

Myofascial injuries occurred in 17% of the cases, which is lower than those reported in a recent systematic review[19] of 15 studies in more than 1500 acute muscle injuries (32%; 95% CI 24%–40%). There is ongoing debate regarding the nomenclature of muscle injuries.[28] In our study, we used the classical anatomical nomenclature.[28] Injuries that were located at the periphery were classified as myofascial injuries. After completing our study, a new histological nomenclature has been proposed.[28] According to this histoarchitectural description, some of these peripheral injuries would have been scored as peripheral myotendinous or myoaponeurotic injuries because the posterior tendon or aponeurosis was focally affected by muscle fiber injury without tendinous involvement.[28]

Strengths and Limitations of the Study

The strength of this study includes a large cohort of 105 acute rectus femoris injuries in adult professional football players. All injuries were confirmed by MRI and scored by an experienced musculoskeletal radiologist, blinded to the clinical findings. We believe that recording of the injury mechanism through history

Copyright © 2021 Wolters Kluwer Health, Inc. Unauthorized reproduction of this article is prohibited.

taking is the most commonly used method reflecting daily clinical practice and therefore increases external applicability.

Regarding the study limitations, it remains unknown whether video analysis of the injury mechanism would have led to other findings. Our cohort consisted of only professional football players competing in one country (Qatar), who all had ready access to MRI. We did not include negative MRI cases (grade 0). Adolescent football players, who are known to be at higher risk of (complete) proximal apophyseal avulsion injuries, were not included in the study. Extrapolating our findings to other (nonkicking) sports, age, and settings should be performed cautiously. Finally, the fact that the study included retrospective and prospective data is a limitation. This study therefore only reported injury mechanism and MRI findings and could not correlate these findings with return to play, clinical outcomes, or rehabilitation.

CONCLUSIONS

In conclusion, rectus femoris injuries represent a significant injury in football athletes, in which kicking might be the most important mechanism related to higher grade injuries and injuries occurring at the proximal free tendon.

ACKNOWLEDGMENTS

The authors thank the staff of the Qatar National Sports Medicine Program (NSMP), Aspetar's Rehabilitation Department, Sports Medicine Department, Outpatient Department, Radiology Department, Research and Education Department, and Orthopedic Department for their contribution to the study.

References

1. Ekstrand J, Hägglund M, Waldén M. Epidemiology of muscle injuries in professional football (soccer). *Am J Sports Med*. 2011;39:1226–1232.
2. Ekstrand J, Askling C, Magnusson H, et al. Return to play after thigh muscle injury in elite football players: implementation and validation of the Munich muscle injury classification. *Br J Sports Med*. 2013;47:769–774.
3. Cross TM. Acute quadriceps muscle strains: magnetic resonance imaging features and prognosis. *Am J Sports Med*. 2004;32:710–719.
4. Hallén A, Ekstrand J. Return to play following muscle injuries in professional footballers. *J Sports Sci*. 2014;32:1229–1236.
5. Witvrouw E, Danneels L, Asselman P, et al. Muscle flexibility as a risk factor for developing muscle injuries in male professional soccer players: a prospective study. *Am J Sports Med*. 2003;31:41–46.
6. Serner A, Tol JL, Jomaah N, et al. Diagnosis of acute groin injuries: a prospective study of 110 athletes. *Am J Sports Med*. 2015;43:1857–1864.
7. Balius R, Maestro A, Pedret C, et al. Central aponeurosis tears of the rectus femoris: practical sonographic prognosis. *Br J Sports Med*. 2009;43:818–824.
8. Fousekis K, Tsepis E, Poulmedis P, et al. Intrinsic risk factors of noncontact quadriceps and hamstring strains in soccer: a prospective study of 100 professional players. *Br J Sports Med*. 2011;45:709–714.
9. Kassarjian A, Rodrigo RM, Santisteban JM. Current concepts in MRI of rectus femoris musculotendinous (myotendinous) and myofascial injuries in elite athletes. *Eur J Radiol*. 2012;81:3763–3771.
10. Bordalo-Rodrigues M, Rosenberg ZS. MR imaging of the proximal rectus femoris musculotendinous unit. *Magn Reson Imaging Clin N Am*. 2005; 13:717–725.
11. Hasselman CT, Best TM, Hughes C, et al. An explanation for various rectus femoris strain injuries using previously undescribed muscle architecture. *Am J Sports Med*. 1995;23:493–499.
12. Mendiguchia J, Alentorn-Geli E, Idoate F, et al. Rectus femoris muscle injuries in football: a clinically relevant review of mechanisms of injury, risk factors and preventive strategies. *Br J Sports Med*. 2013;47:359–366.
13. Hughes C, Hasselman CT, Best TM, et al. Incomplete, intrasubstance strain injuries of the rectus femoris muscle. *Am J Sports Med*. 1995;23: 500–506.
14. Brophy RH, Wright RW, Powell JW, et al. Injuries to kickers in American football: the national football league experience. *Am J Sports Med*. 2010; 38:1166–1173.
15. Eckard TG, Kerr ZY, Padua DA, et al. Epidemiology of quadriceps strains in national collegiate athletic association athletes, 2009–2010 through 2014–2015. *J Athl Train*. 2017;52:474–481.
16. Fuller CW, Ekstrand J, Junge A, et al. Consensus statement on injury definitions and data collection procedures in studies of football (soccer) injuries. *Br J Sports Med*. 2006;40:193.
17. Ekstrand J, Healy JC, Waldén M, et al. Hamstring muscle injuries in professional football: the correlation of MRI findings with return to play. *Br J Sports Med*. 2012;46:112.
18. Serner A, Weir A, Tol JL, et al. Characteristics of acute groin injuries in the hip flexor muscles—a detailed MRI study in athletes. *Scand J Med Sci Sports*. 2018;28:677–685.
19. Wilke J, Hespanhol L, Behrens M. Is it all about the fascia? A systematic review and meta-analysis of the prevalence of extramuscular connective tissue lesions in muscle strain injury. *Orthop J Sports Med*. 2019;7: 232596711988850.
20. Ouellette H, Thomas BJ, Nelson E, et al. MR imaging of rectus femoris origin injuries. *Skeletal Radiol*. 2006;35:665–672.
21. Peetrons P. Ultrasound of muscles. *Eur Radiol*. 2002;12:35–43.
22. Hancock CR, Sanders TG, Zlatkin MB, et al. Flexor femoris muscle complex: grading systems used to describe the complete spectrum of injury. *Clin Imaging*. 2009;33:130–135.
23. Comin J, Malliaras P, Baquie P, et al. Return to competitive play after hamstring injuries involving disruption of the central tendon. *Am J Sports Med*. 2013;41:111–115.
24. Kassarjian A, Rodrigo RM, Santisteban JM. Intramuscular degloving injuries to the rectus femoris: findings at MRI. *Am J Roentgenol*. 2014; 202:W475–W480.
25. Serner A, Mosler AB, Tol JL, et al. Mechanisms of acute adductor longus injuries in male football players: a systematic visual video analysis. *Br J Sports Med*. 2019;53:158–164.
26. Askling CM, Tengvar M, Saartok T, et al. Acute first-time hamstring strains during high-speed running: a longitudinal study including clinical and magnetic resonance imaging findings. *Am J Sports Med*. 2007;35: 197–206.
27. Askling CM, Tengvar M, Saartok T, et al. Acute first-time hamstring strains during slow-speed stretching: clinical, magnetic resonance imaging, and recovery characteristics. *Am J Sports Med*. 2007;35: 1716–1724.
28. Study Group of the Muscle and Tendon System from the Spanish Society of Sports Traumatology, Balius R, Blasi M, Pedret C, et al. A histoarchitectural approach to skeletal muscle injury: searching for a common nomenclature. *Orthop J Sports Med*. 2020;8: 232596712090909.

Copyright © 2021 Wolters Kluwer Health, Inc. Unauthorized reproduction of this article is prohibited.